

Treatment of Medium-Size Congenital Melanocytic Nevi (CMN) by New Combined Laser Therapy: Better Results and Fewer Complications*

MOHAMED MAHMOUD M. ABDELAAL, M.D., A.B.L.S.; IMAN M. AL-LIETHY, M.D.;
SHERINE M. ABOUL FOTOUH, M.D. and KARIM S. MASSOUD, M.D., A.B.L.S.

The Department of Plastic Surgery, Faculty of Medicine, Ain Shams University.

ABSTRACT

Treating congenital melanocytic nevi (CMN) by single laser without complications are difficult because of the deep nature of pigments in these lesions. The combined laser therapy by using non-selective lasers (NMRL or CO₂ laser) and one of the selective lasers (Q-switched lasers) was tried with better results. In this study new combination was tried on ten patients with medium size CMN by using Er:YAG laser and q-switched Nd:YAG laser. This group was compared with another two different treatment modalities, where q-switched Nd:YAG laser alone was used as a single modality to treat ten patients in one group (control group) and both q-switched Nd:YAG and CO₂ lasers were used simultaneously in the second group to treat another ten patients. The total treatment sessions were 132 sessions, and the minimal follow up period was 6 months. Eighty percent of patients treated by erbium laser combinations had good to excellent results and fewer incidences of complications. While seventy percent of patients treated with the CO₂ combination showed good to excellent results but with higher incidence of moderate to severe scarring, while patients treated with q-switched Nd:YAG laser had no improvement. By combining resurfacing and selective lasers, treatment of CMN has become possible which was not the case with the q-switched lasers alone. Er:YAG laser can be used instead of the CO₂ laser because it causes less thermal damage, less complications, and faster wound healing.

INTRODUCTION

Benign pigmented skin lesions are classified on developmental basis and according to the depth, and the type of melanin laden cells. So, they demonstrate different responses to treatments [1,2].

Congenital melanocytic nevus (CMN) is present at birth in about 1% to 2% of newborn infants. Congenital pigmented nevi have been divided according to their surface areas into three size ranges. Small lesions with a diameter less than

2cm, intermediate-size lesions are those between 2 and 20cm, and giant lesions (GCMN) with diameters over 20cm "Bathing trunk nevus", "Garment nevi" [3].

The non-giant congenital nevi are usually slightly raised, uniformly pigmented with sharp borders, and stable growth pattern. At birth, congenital nevi may be very pale macular lesions. They frequently darken and thicken with age (flat or verrucoid) and may develop outgrowths of coarse hair. At puberty, hair growth and pigmentation progressively increases [4].

Treatment of congenital melanocytic nevi (CMN) is extremely controversial because these lesions extend into the deepest reticular dermis and often into the subcutaneous fat, as it is impossible to remove every nevus cell in CMN particularly when there is involvement of vital structures [5]. Different modalities were tried for treating CMN including; surgical excision, cryotherapy, dermabrasion, salabrasion, electrodesiccation, chemical peel, infrared coagulation, Argon laser, and CO₂ laser. These treatments were either ineffective in removing the deep pigments or they end by complications such as scar formation, dyschromia, and/or frequent recurrence [6].

Q-switched lasers work by the theory of "selective photothermolysis" where certain laser parameters can affect a specific target while sparing the surrounding normal structures. Q-switched laser with their very short pulse width (nanometers) can be selectively destroy the melanin laden organelles within the cells (melanosomes) sparing the other normal components. Q-switched lasers proved to be a valuable tool in the treatment of superficial pigmented lesions [7]. But they showed

* The paper presented at the 30th Summer Meeting of the Egyptian Society of Plastic and Reconstructive Surgeons, Alexandria, Egypt, 8-9 September, 2005.

minimal effect in the treatment of CMN with very high rate of recurrence after very long periods of treatment sessions, because it is unlikely that these lasers will destroy all pigmented cells especially within the deeper layers of the skin [8,9,10].

Combined treatment modality has been proposed by many authors to target at first the superficial nevomelanocytic components by one of the non-selective lasers followed by selective lasers for the deep components. The aim of this combination is to improve the percentage of clearance and decrease the incidence of complications. Different combinations have been tried within the last few years. Combined therapy using CO₂ laser q-switched ruby laser (QSRL) was tried, and the results were compared with those treated with QSRL alone [11]. Some other combinations involve the use of normal mode ruby laser (NMRL) first, to remove the epidermis followed by multiple passes with one of q-switched lasers; q-switched ruby laser (QSRL) [12,13,14], or q-switched Alexandrite laser (QSAL) [15]. New combinations are still under investigation to optimize the results.

PATIENTS AND METHODS

A total of thirty patients with congenital melanocytic nevi were treated with three lasers in the laser unit in plastic surgery department, Ain-Shams University in the period from June 2003 to May 2005. Twelve were males (40%), and eighteen were females (60%). Their age ranged from six months to fifteen years. The patients were divided randomly into three groups, ten patients in each group. Group I included four males and six females. Group II included three males and seven females, and group III included five males and five females. According to Fitzpatrick's classifications, their skin types ranged from II to V.

Pediatric age only (less than 18 years) with medium sized congenital melanocytic nevi were treated in this study, and all other patients with giant congenital melanocytic nevi were excluded as they may be associated with higher incidence of malignant transformation especially melanoma, which makes the treatment controversial. Lesions were distributed over various parts of the body; face, neck, arms, forearm, hands and legs.

Patients in the first group (control group) were treated by q-switched Nd:YAG laser (1064nm wavelength, and 30nsec pulse-width delivered through an articulated arm and 2-6mm focusing hand-piece delivering high peak energy fluencies up to 10 J/cm²). Treatment sessions were repeated every month for a maximum of ten treatment ses-

sions. Patients in this group usually required no anesthesia.

Patients in group II were treated by simultaneous use of both CO₂ laser (10,600nm wavelength, continuous mode with duty cycle 50%, in 0.8mm spot size through an articulated arm with power output 8 to 14W) and q-switched Nd:YAG laser. While patients in group III were treated by simultaneous use of both Er:YAG laser (2.940μm wavelength, and 350μsec pulse-width with energy fluence ranging from 10 to 15 J/cm² through an articulated arm) and q-switched Nd:YAG laser. CO₂ and Er:YAG lasers were used to ablate epidermal and upper papillary layers of skin with the abnormal pigments content, till reaching a macroscopic safe histological depth (upper reticular dermis). In the upper reticular dermis; bleeding becomes splotchy, and transudate become more profuse. At this point, it is best to proceed no further [16].

Patients in group II and III usually required anesthesia either local (Xylocaine 2%) or general (intravenous ketamine) because of the heat produced by the non-selective lasers. Extra-thin Duo-derm dressing was usually applied after each treatment session until complete healing (five to seven days). All patients with lesions over sun exposed areas continued on sunblock during daytime and 4% hydroquinone cream nightly for three to six months following the last session. Treatment sessions were repeated every two months.

Follow-up ranged from 6 months to one year. The results were interpreted by comparing preoperative and postoperative standardized digital photography (Nikon-coolpex 995, 3,3 Mpx, 5X optical zoom) by a panel of three observers (one physician, one laser nurse, and one of patient's family). Results were classified as excellent (improvement more than 75%), good (51-75%), fair (26-50%), and poor (<25%) [17]. Complications were also graded into either absent (0), mild (1), or moderate to severe (2) [18].

RESULTS

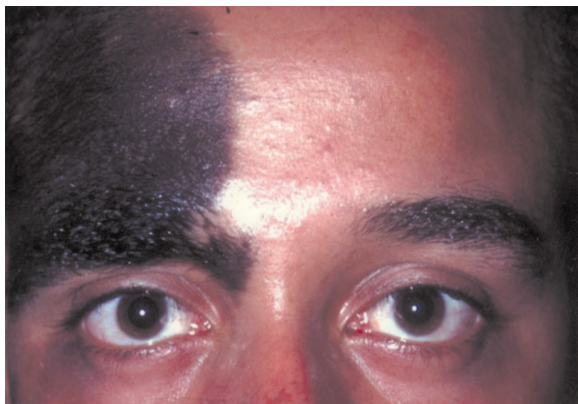Q-switched Nd:YAG laser (QSNd:YAG) was used with a total of fifty-five sessions in group-I, with treatments ranged from four to ten (mean of 5.5 sessions). Four passes were done using 4mm hand piece without overlapping with fluencies ranged from 5 to 7 J/cm² (Table 1). In this group seven patients (70%) had slight lightening of color (<25%) after four to five sessions (mean of 4.6 sessions). Two patients had fair results (26-50%) after six and seven treatment sessions (mean of 6.5 sessions), and only one patient had more than

50% clearance after ten treatment sessions (Table 2). Repigmentation occurred in all patients during the follow up period, and patients refused to proceed in treatment because of the unsatisfactory results.

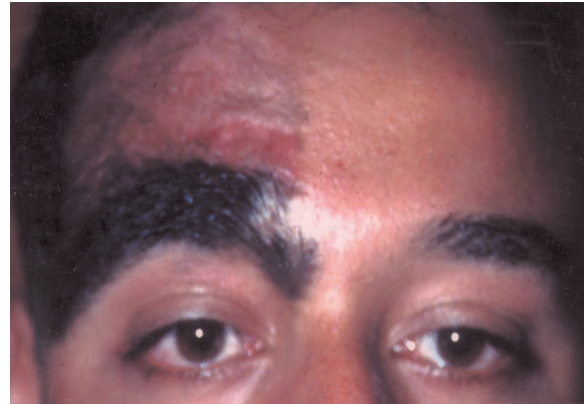Thirty two treatment sessions were done using both CO₂ and Q-switched Nd:YAG lasers in group-II. Number of treatments ranged from two to five sessions (mean of 3.2 sessions). Two to three passes with CO₂ laser were done followed by four passes with Q-switched Nd:YAG laser. Complete healing occurred within seven to ten days (Table 1). One patient had poor results after two sessions. Two patients had fair results after five treatment sessions (mean of 2.5 sessions). Three patients showed good results after ten sessions (mean of 3.3 sessions), and four patients had excellent results after fifteen sessions (mean of 3.75 sessions) (Fig. 1). Patients in this group had higher rates of complications in

the form of moderate to severe scarring and textural changes (Table 2). It was also noticed that most of those patients complained of prolonged erythema (3 to 6 months).

Forty five sessions were done over the study period in group-III by using both Er:YAG laser and Q-switched Nd:YAG laser (mean of 4.5 sessions). Four to six passes with Er:YAG laser were enough to reach the desired resurfacing end points, followed by four passes with Q-switched Nd:YAG laser. Complete healing usually occurred within the first week (5-7 days). Two patients had fair results after six treatment sessions (mean of 3 sessions). Three patients showed 50% to 75% clearance after a total of thirteen sessions (mean of 4.3 session), and five patients had more than 75% improvement after twenty six sessions (mean 5.2 session) (Fig. 2). Mild textural changes and scarring occurred in four patients during the follow up period in this group (Table 2).



[A]



[B]

Fig. (1): Fourteen years old patient with CMN of the forehead before, and after four sessions with CO₂ & q-switched Nd:YAG lasers with moderate scarring (G-II).

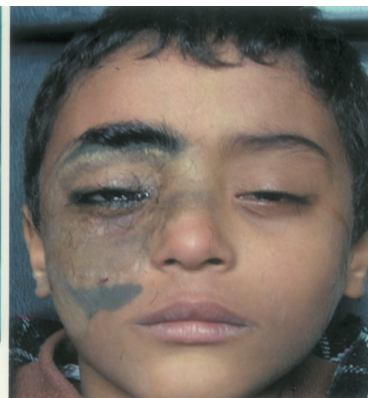
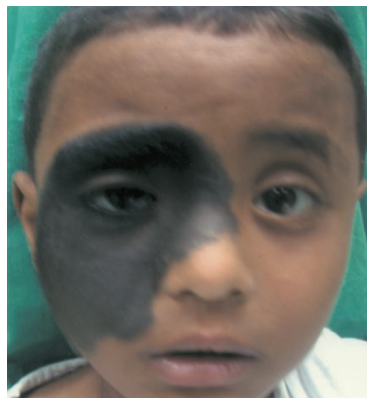
Fig. (2): Seven years old patient with CMN before (left), and after six sessions with Er:YAG & q-switched Nd:YAG lasers (right) with minimal scarring (G-III).

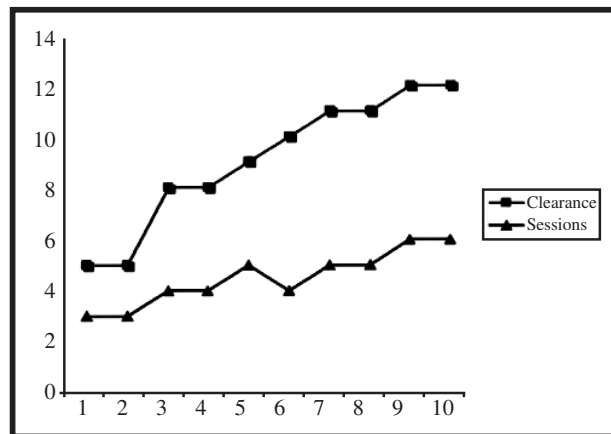


Fig. (3): The relation between number of treatment sessions and percentage of clearance in group III.

Table (1): Treatment parameters of patients in all groups.

	Lasers	No. of sessions	Time interval	Power fluence	No. of passes	Healing time
Group I	QSNd:YAG	55	1 month	5-7J/cm ²	4	3-5d
Group II	CO ₂ & QSNd:YAG	32	2-3 month	8-14W 5-7J/cm ²	2-3 4	7-10d
Group III	Er:YAG & QSNd:YAG	45	2-3 month	10-15J/cm ² 5-7J/cm ²	4-6 4	5-7d

Table (2): Percentage of clearance and complications in relation to number of sessions in all groups.

	Mean of sessions	Clearance/Sessions								Complications
		% 0-25	No. session	% 0-25	No. session	% 0-25	No. session	% 0-25	No. session	
Group I	5.5	7/32		2/13		1/10		–		0
Group II	3.2	1/2		2/5		3/10		4/15		2
Group III	4.5	–		2/6		3/13		5/26		1

DISCUSSION

Congenital Melanocytic Nevi (CMN) are common lesions present at birth. Medium sized congenital nevi (2-20 cm² in diameter) have low reported lifetime risk of developing melanoma, but GCMN (>20 cm² in diameter) have a reported lifetime risk of 5% to 10% of developing melanoma [5]. The use of laser in the treatment of CMN is controversial. Some feel that lasers can reduce the melanocytic mass and the risk of malignancy, but others are more concerned about the potential increase in the risk of sub-lethal laser damage [19].

Argon laser, CO₂ laser, and NMRL have been used to ablate nevomelanocytic lesions, including CMN, but soon were faced with limitations. The disadvantages are the pain, scarring, secondary infection, and the recurrence of the deeper lesions (especially in the older children, who had a migra-

tion of the nevomelanocytes as far as the hypodermis). After the initial laser destruction of congenital nevi, a repopulation of the initially depleted layers occurs within 6 months from the remaining dermal nests [20].

The introduction of short pulsed lasers has made it possible to treat various pigmented skin lesions with lower rate of recurrences and complications. Available short pulsed lasers include green light pulsed lasers such as the pigmented pulsed dye laser (510nm, 300nsec) and the frequency-doubled q-switched Nd:YAG laser (KTP-532nm, 5-10nsec). As green light is absorbed to a high degree in melanin but penetrates just superficially into the skin, these lasers can only be used for the treatment of pigmented epidermal lesions. Red light pulsed lasers include the q-switched ruby laser (694nm, 20-50nsec), the q-switched Alexandrite laser (755nm, 5-100nsec). Infrared pulsed

lasers such as the q-switched Nd:YAG laser (1064nm, 10nsec). They have a low absorption by melanin, but deeper penetrating potential through the skin, and therefore might be even more suitable for treating more deep dermal pigmented lesions [5].

To date, almost all of published series of CMN treated with q-switched lasers have indicated that q-switched lasers lighten and clear superficial pigmentations from CMN without scarring, but these results are not permanent with recurrence after the discontinuation of treatment [14]. Therefore, single laser modality is not sufficient to cause complete removal of nevomelanocytic nests in CMN. Combined treatment modality has been proposed by many authors to target both superficial and deep nevomelanocytic components. The theory of combined treatment based on increase the efficiency of selective lasers (Q-switched lasers) to affect the deep nevomelanocytic components. Combined treatment begins with the removal of the epidermis with all its superficial nevomelanocytes using non-selective lasers. This enables a greater degree of penetration by the q-switched lasers [5].

Different combinations have been tried within the last few years. Some combinations involve the use of NMRL first, to remove the epidermis followed by multiple passes with one of q-switched lasers; q-switched ruby laser (QSRL) [12,13,14], q-switched Alexandrite laser (QSAL) [15].

Lesions treated by combining NMRL with either QSRL or QSAL showed better clinical response (excellent to good) with a higher percentage of lightening (64.45%-72.43%) than the single laser-treated lesions. But, none of the nevi had complete clearance of pigmentations after one treatment session. Therefore, multiple (at least four) treatment sessions are recommended at 4-weeks intervals until complete clearing is achieved [14].

CO₂ laser (continuous emission of 2 to 5W) was used in a different combination for the treatment of CMN. The combined treatment begins with CO₂ laser ablation (3 to 5 passes). In a second step of the treatment three machines were used; the q-switched Nd:YAG laser, the q-switched KTP laser (532nm) or intense pulsed light with wide band (515-1200nm) [21].

Concomitant combined therapy using CO₂ laser (resurfacing laser) and a selective QSRL was also tried, and the results were compared with those treated with QSRL alone. Fifteen patients with CMN were treated with this combination, 12 (80%) showed good to excellent results (more than 75%

clearance). The authors concluded that; "By combining resurfacing and selective lasers, the treatment period has been reduced by 2 to 3 months with better clearance, and the number of treatments has been reduced two-to three fold" [11].

Er:YAG laser is preferable in the resurfacing procedures over the CO₂ laser, as Er:YAG laser causes less thermal damage and promotes faster wound healing [5]. In the current study, the efficacy of combined therapy using the Q-switched Nd:YAG laser with either Er:YAG laser (G-III) or CO₂ laser (G-II) was compared.

The best clinical results were achieved in group III where Er:YAG laser was used in conjunction with Q-switched Nd:YAG laser. Fifty percent of patients in this group showed an excellent result while only forty percent in group II had the same results. Slight clearance was noticed all patients of group I where Q-switched Nd:YAG was used as a single treatment modality.

Although the percentage of clearance was high in group II, yet moderate to severe textural changes was noticed in almost all patients. Other disadvantages in this group were lack of depth control, and delayed wound healing (7-10 days). On the other hand, healing was faster in group III without major complications. This may be attributed to the heat generated by CO₂ laser that causes coagulative necrosis in deeper layers.

After treating over 100 Japanese patients Watanabe and Takahashi stated that "the degree of lightening was found to be directly proportional to the number of treatments performed" [22]. In our work, it was noticed that the percentage of clearance is in direct proportion to the number of treatment sessions in group II as a mean of 2.5, 3.3, 4 treatment session were needed to have fair, good and excellent results, respectively. While in group III a mean of 3, 4.3, and 5.2 treatment sessions were needed to achieve the same results, respectively. So, it was noted that the more the treatment sessions the more the percentage of clearance using the combined laser technique (Fig. 2).

CO₂ or Er:YAG lasers alone have limited role in treating very deep dermal lesions, as they will alter the collagen fibers within the dermis leading to healing by scar tissue. Also, Q-switched lasers (ruby, alexandrite, or Nd:YAG lasers) have limited ability to destroy all pigmented cells especially in the deep layers, as there is loss of big amount of energy due to absorption and scattering of laser light within the skin [23]. The idea of combining

two modalities is to lighten deep resistant lesions by lesser numbers of treatment sessions (decrease the coast and time of treatment) to achieve better results (more percentage of clearance), and with less complications (scarring, textural changes, and recurrence).

By simultaneous usage of Er:YAG and Q-switched Nd:YAG lasers (G-III), we achieved better results as regard the percentage of clearance and the incidence of complications than the CO₂ laser combination (G-II). This combination is an effective method for treating medium-size CMN with minimal scarring or textural changes. But possible deleterious long-term effects of laser-induced changes on the remaining nevomelanocytes deserve consideration. So, future studies should focus on the long term effects of the combined lasers treatment on CMN and its effectiveness in relation to histological types.

REFERENCES

- 1- Cullen S.I.: Incidence of nevi. *Arch. Dermatol.*, 86: 88-89, 1962.
- 2- Fitzpatrick T.B.: The velocity and practicality of sun-reaction to skin types I through VI. *Arch. Dermatol.*, 124: 869-71, 1981.
- 3- Rivers J.K., Frederiksen P.C. and Dibelin C.A.: Prevalence survey of dermatosis in Australian neonates. *J. Am. Acad. Dermatol.*, 23: 77, 1990.
- 4- Reynolds N., Kenealy J. and Mercer N.: Carbon dioxide laser dermabrasion for giant congenital melanocytic nevi. *Plast. Reconstr. Surg.*, 111: 2209, 2003.
- 5- Michel J.L.: Laser therapy of giant congenital melanocytic nevi. *Europ. J. Dermatol.*, 13 (1): 57-64, 2003.
- 6- Colver G.B., Lones R.L. and Cherry G.W.: Precise dermal damage with an infrared coagulator. *Br. J. Dermatol.*, 114: 603, 1986.
- 7- Siskind V., Darlington S., Green L. and Green A.: Evolution of melanocytic nevi on the faces and necks of adolescents: A 4y longitudinal study. *J. Invest. Dermatol.*, 118 (3): 500-4, 2002.
- 8- Khan R.: Lasers in plastic surgery. *J. Tissue Viability*, 11 (3): 103-7, 2001.
- 9- Goldberg D.J.: Benign pigmented lesions of the skin: Treatment with the Q-switched ruby laser. *J. Dermatol. Surg. Oncol.*, 19: 376-79, 1993.
- 10- Vibhagool C., Pyers H.R. and Grevelink J.N.: Treatment of small nevomelanocytic nevi with q-switched Ruby laser. *J. Am. Acad. Dermatol.*, 36: 738-741, 1997.
- 11- Park S.H., Koo S.H. and Choi E.O.: Combined laser therapy for difficult dermal pigmentation: Resurfacing and selective photothermolysis. *Ann. Plast. Surg.*, 47 (1): 31-36, 2001.
- 12- Duke D., Byers H.R. and Sober A.J.: Treatment of benign and atypical nevi with the normal mode ruby laser and the q-switched ruby laser. *Arch. Dermatol.*, 135: 290-296, 1999.
- 13- Kono T., Nozaki M., Chan H.H., Sasaki K. and Kwon S.G.: Combined use of normal mode and Q-switched ruby lasers in the treatment of congenital melanocytic nevi. *British J. Plast. Surg.*, 54 (7): 640-3, 2001.
- 14- Kono T., Ercocen A.R., Chan H.H., Kikuchi Y., Isago T. and Nozaki: Effectiveness of normal-mode ruby laser and the combined (normal-mode plus Q-switched) ruby laser in the treatment of congenital melanocytic nevi: A comparative study. *Ann. Plast. Surg.*, 49 (5): 476-485, 2002.
- 15- Kono T., Ercocen A.R., Kikuchi Y., Isago T., Honda T. and Nozaki M.A.: Giant melanocytic nevus treated with combined use of normal mode ruby laser and Q-switched Alexandrite laser. *J. Dermatol.*, 30: 538-542, 2003.
- 16- Weinstien C. and Roberts T.L.: Aesthetic skin resurfacing with high-energy ultrapulsed CO₂ laser. *Clin. Plast. Surg.*, 24: 379-401, 1997.
- 17- Kilmer S.L., Lee M.S., Grevelink J.M., Flotte T.J. and Anderson R.R.: The Q-switched Nd:YAG laser effectively treats tattoos. *Arch. Dermatol.*, 129: 971-78, 1993.
- 18- Taylor C.R. and Anderson R.R.: Treatment of benign pigmented epidermal lesion by Q-switched ruby laser. *Int. J. Dermat.*, 32: 908-12, 1993.
- 19- Anderson R.R., Margolis R.J. and Watanabe S.: Selective photothermolysis of cutaneous pigmentation by Q-switched Nd:YAG laser pulses at 1064, 532, and 355nm. *J. Invest. Dermatol.*, 92: 28-32, 1989.
- 20- Oshiro T. and Maryuyama Y.: The ruby and argon lasers in the treatment of nevi. *Ann. Acad. Med. Singapore*, 12: 388-95, 1983.
- 21- Cisneros J.L. and Del Rio R.: Laser treatment of congenital nevus. *Europ. J. Dermatol.*, 13 (1): 57-64, 2003.
- 22- Watanabe S., Takahashi H.: Treatment of nevus of Ota with Q-switched ruby laser. *N. Eng. J. Med.*, 331: 1745-1750, 1994.
- 23- Chong S.J., Jeong E., Park H.J., Lee J.Y. and Cho B.: Treatment of congenital nevomelanocytic nevi with the CO₂ and Q-switched alexandrite lasers. *Dermatol. Surg.*, 31 (5): 518-21, 2005.